

Another interesting fact in this case is the rapidity of response after such a considerable period of aphasia, indicating that the cerebral structures involved were functionally depressed and not destroyed. The immediate change in the psychiatric picture after the return of the speech function was especially striking and very instructive.

We would like to thank Dr. R. E. Hemphill for advice and permission to publish this article.

S. SMITH, M.D., M.R.C.P., D.P.M.

E. C. TURTON, M.B., M.Sc., M.R.C.P., D.P.M.

Barrow Hospital, Barrow Gurney, near Bristol.

An Unusual Case of Hypoprothrombinaemia Haemorrhagica

Haemorrhagic states associated with hypoprothrombinaemia are well known to occur clinically in two sets of conditions—in the neonatal period and in liver diseases with obstructive jaundice. The case reported here, however, falls in neither category, and is presented because of its unusual features.

Case Report

The patient, a woman aged 50, complained of tenderness of the extremities along with the appearance of "reddish patches" of varying sizes and distribution in the limbs and trunk. She had been apparently well until early the previous evening, and had not noticed any pinkish areas on her body or experienced any discomfort. She was definite that all her symptoms developed in the course of a few hours, late the previous evening and overnight. Patches were appearing continuously and increasing in size. The most careful questioning failed to reveal any allergic basis whatsoever for these symptoms. There was no history of bleeding from any of the orifices. Her periods had stopped four years ago. She was sure that there was nothing unusual about her diet or surroundings which could have caused these symptoms, and she had not taken any drugs or unusual foods.

An exactly similar attack ten years ago was characterized by the rather abrupt occurrence of pinkish patches over her extremities and trunk. The patches lasted then for a few days, gradually turned dusky, and disappeared under some treatment the details of which were not available.

On examination the patient seemed obviously ill but not toxic, and was unable to walk or move about normally

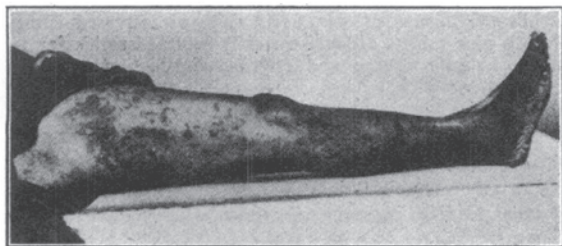

FIG. 1.—Condition before treatment.

because of the tenderness in her limbs. Her temperature was normal. There was evidence of extensive subcutaneous haemorrhage in the extremities and trunk. The lateral aspects of both thighs presented large pinkish areas of subcutaneous haemorrhage (Fig. 1). The rest of the limbs and trunk showed haemorrhagic patches of varying sizes ranging from punctate spots to large patches. The largest was an oval-shaped patch in the right thigh measuring 6 by 3 in. (15 by 7.5 cm.). The trunk showed fairly extensive areas of subcutaneous haemorrhage, particularly in the lower back. The upper limbs were less heavily

involved. The face was exempt; the tongue and buccal mucous membrane were normal. These pinkish patches were not elevated above the skin surface and were not itchy.

Active movements of the extremities were painful, and vigorous passive movements were also resented. The joints were not swollen or particularly tender; the heart and lungs were normal; the blood pressure was 100/70 mm. Hg; no abnormality of the central nervous system was detected; the liver and spleen were not palpable; and examination of the abdomen revealed no abnormality.

Haematological examination showed: red cells, 4,300,000 per c.mm.; Hb, 10.6 g.%; P.C.V., 34%; M.C.V., 80.4 μ^3 ; M.C.H., 25.1 $\mu\mu\text{g}$.; M.C.H.C., 31%; white cells, 7,200 per c.mm.; platelets, 235,000 per c.mm.; prothrombin time, 125 seconds (Quick's method). The bleeding and clotting times were normal. Fractional gastric analysis showed nothing unusual. Examination of the urine and stools revealed nothing abnormal.

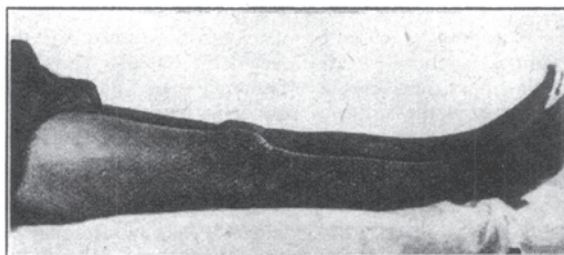


FIG. 2.—After treatment.

Because of the marked increase in the prothrombin time vitamin K was tried, 10 mg. of vitamin K (2-methyl-1,4-naphthohydroquinone; "synkavit") being injected intramuscularly daily for the first four days and on the sixth and seventh days. Once the treatment was started no fresh areas of bleeding were noticed. Gradually the pinkish areas turned dusky and began to fade, and by the fifth day no trace of them was left (Fig. 2). The tenderness of the limbs also rapidly disappeared.

The prothrombin time showed a progressive decline from 125 seconds before treatment to 50 seconds on the third day of treatment, 18 seconds on the fifth day, and 15 seconds on the seventh day.

A follow-up of the patient shows that she is keeping in good health.

Comment

The occurrence of hypoprothrombinaemia haemorrhagica in the neonatal period and in obstructive jaundice is well recognized and explained. In the case reported here, however, haemorrhagic manifestations associated with hypoprothrombinaemia were seen in an adult not suffering from any liver disorder. There is apparently no explanation for the hypoprothrombinaemia in this case. The diet was apparently adequate and there was no intestinal upset. Kallos (1946) has reported beneficial results from treatment with vitamin K in cases of angioneurotic oedema without allergic bases but associated with hypoprothrombinaemia. We are not aware of any reports of purpuric manifestations associated with hypoprothrombinaemia in adults not suffering from liver disorders.

We are grateful to Messrs. Hoffmann-LaRoche for the free supply of synkavit.

C. GOPALAN, M.D., Ph.D.

P. S. VENKATACHALAM, M.B., B.S.

Nutrition Research Laboratories, Indian Council of Medical Research, Coonoor, South India.

REFERENCE

Kallos, P. (1946). *Gastroenterologia*, 71, 171.